



A case study on Prolapsed Lumbar Intervertebral Disease (PLID) acupuncture treatment in Bangladesh

Dr. S. M. Shahidul Islam¹, Dr. Hui Hui Li², Sabina Yasmin³ and Mohammad Shajib Sheik⁴

¹ Visiting Consultant & Acupuncture Specialist, Suo-Xi Hospital (Acupuncture), Shaan Tower, Chamelibag, Santinagar, Dhaka, Bangladesh

² Consultant, Department of Orthopedics and Traumatology, Peoples Hospital of Chinese Medicine, Ruian City, China

³ CEO, Suo-Xi Hospital (Acupuncture), Shaan Tower, Chamelibag, Santinagar, Dhaka, Bangladesh

⁴ Managing Director, Suo-Xi Hospital (Acupuncture), Shaan Tower, Chamelibag, Santinagar, Dhaka, Bangladesh

Correspondence Author: Dr. S. M. Shahidul Islam

Received 27 Feb 2023; Accepted 10 Apr 2023; Published 18 Apr 2023

Abstract

Background: Common medical problems include low back discomfort and sciatica. This shift will result in fewer hours worked and less strain on the national economy. Before beginning treatment, these individuals need to undergo a thorough medical evaluation. This is more likely to develop if inadequate medical or surgical treatment is provided. Examining whether or how acupuncture may enhance conventional PLID treatment is the goal of this study.

Methods: This inquiry took place at SUOXI Healthcare Limited in Shantinagar, Dhaka, Bangladesh. A 33-year-old young male patient has been complaining of lower back discomfort for the last five years. It had been five years since he had found relief from the pain in his lower back, but now he was pain-free.

Results: The results of the follow-up study were excellent. The patient's lower back pain, which he had been suffering for five years, was no longer present. **Conclusion:** Patients with PLID may benefit from acupuncture, according to this research.

Keywords: PLID, acupuncture, physiotherapy, mobilization, manipulation, stretching, chinese method, low back-pain, lumbar disc

Introduction

A recent study showed that 23% of adults in affluent nations suffer with chronic non-specific low back pain (CNSLP) that cannot be attributed to any one particular cause ^[1]. Medical costs, time away from work, and inability to work are all inflated by CNLBP. Non-drug treatments, such as exercise and multidisciplinary and behavioral treatment, have been shown to be effective ^[4, 5] for chronic back pain, despite concerns about the benefits and potential harms of medication like paracetamol, non-steroidal anti-inflammatory drugs (NSAIDs), and opioids ^[2, 3]. Large biomechanical stresses may cause disc material to leak out of a healthy, normal disc in the case of a catastrophic collapse of the annular fibers. Condivergent disc herniation (PLID) or sliding disc (slipped disc) happens when the annulus fibrosus and annulus radculus of an intervertebral disc are torn. Loss of bowel or bladder control is very unusual and requires prompt medical intervention ^[5, 6, 7]. Pain in the lower back and legs might be the result of a herniated or ruptured disc in the lumbar spine. Pain, numbness, or tingling in the legs are some of the other symptoms that a herniated disc might bring on. The discomfort appears to become worse when you cough, sneeze, or bend over. Prolapsed disc disease is caused by dehydration of the disc matrix in the intervertebral space. Lumbar disc disease is a broad term that encompasses a variety of back and sciatica pain conditions. This article depicts a herniated disc in the lumbar spine. Degeneration of the lumbar discs is blamed for about a third of all occurrences of back pain. If the hernia compresses the nerve fibers that provide feeling to the skin, the

patient may experience discomfort, weakening in the limbs, and a loss of touch. When a nerve is injured, pain travels down one leg, down the outside of the calf, and into the foot (sciatica). Nerve root impingement most often occurs between the fourth and fifth lumbar vertebrae, or between the fifth lumbar vertebra and the first sacral segment. Occupations in the construction industry, manufacturing, food service, and transportation were all linked to an increased risk of PLID. Every motorist, professional or not, has a higher risk of an accident when PLID is present. Jobs for women in the domestic service industry, the private service sector, and the garment industry are all dangerous. These ladies are equally represented in the workforce as their male counterparts. According to healthcare records, those with PLID are more likely to end up in the hospital than their coworkers who do not have the condition.

Case report

A patient who was a young guy aged 33 and who had been complaining of consistently growing low back pain for the previous five years arrived to our institution. The patient's complaint was that the pain had been becoming worse over time. The patient's primary concern was that the pain had become steadily worse during the course of their treatment. Before deciding to seek medical assistance for the issue, it had been seven years since he had first reported having difficulties with it. During the course of this experiment that was conducted inside the confines of a laboratory in a setting that was kept under continual monitoring, an atmosphere that was

maintained under these conditions was used. In addition, the findings of an MRI performed on the cervical spine show that the results suggest that the presence of PLID is compatible with these discoveries, which is consistent with what was found. This is consistent with the findings of the investigation.

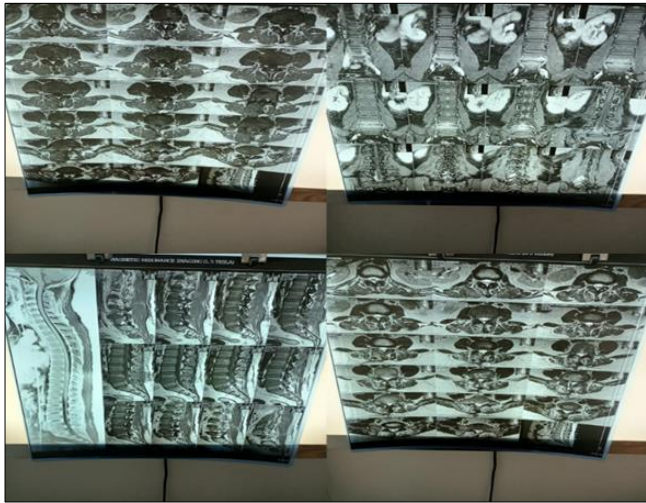


Fig A: MRI of cervical spine revealing PLID

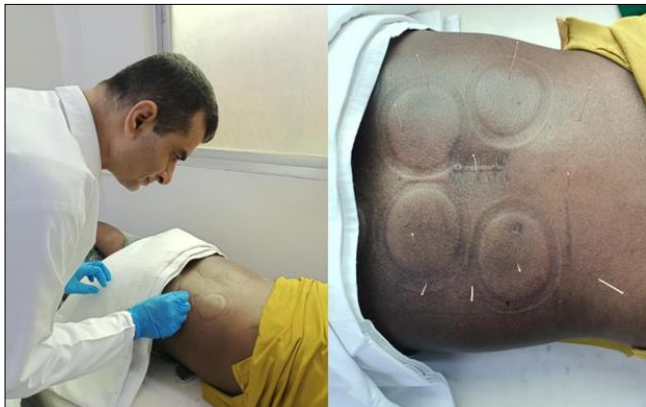

Fig B: MRI of cervical spine revealing PLID

Mobilization, manipulation, and stretching of the lumbar spine, in addition to acupuncture of the lower back, are often utilized as the initial lines of defense in the treatment of low back pain. Acupuncture of the lower back is also sometimes used. One of the treatments that we do is a mix of lumbar mobility and manipulation, and this helps to put the patient at ease. The results of the follow-up inquiry were encouraging, and the inferences that were derived from those findings were likewise, on the whole, good. After receiving acupuncture on his lower back for the fourth time, the patient's health improved noticeably, indicating that the treatment was effective. When the patient's chronic pain in his lower back mysteriously started to alleviate all of a sudden, he was taken aback.

Discussion

Since it is the most prevalent orthopedic disease, a prolapsed intervertebral disc is the most common cause of low back discomfort (lower back pain). Fenestration of the vertebral lamina is a common surgical procedure for treating lumbar intervertebral disc prolapse [8, 9]. This medication's beneficial effects on inflammation, swelling, blood flow, and collateral dredging are accompanied by a complete absence of negative

effects [10]. To effectively use acupuncture and moxibustion, one must be familiar with the concepts of channels and collaterals. In the following paragraphs, we'll explore these ideas in further detail. New research shows that the nervous and muscular systems work together to generate channels and collaterals that are then utilised by other organs and systems [11, 12]. A 33-year-old man came to our clinic with a 10-year history of low back pain that had been getting in the way of his daily life. It was difficult to adapt to living with constant, excruciating pain. Despite the fact that we were responsible for a large percentage of the assessments, we did it on our own initiative and paid for all of the resources we used. The MRI of the cervical spine was utilized to confirm the diagnosis of PLID in this patient. It was found at an early stage that there was degeneration in the lumbar spine. The patient's symptoms improved with the combined care of acupuncture and physical therapy. When all factors were considered, it was clear that this was the optimal option. The patient reports considerable improvement in their lower back pain after receiving four sessions of acupuncture. Nevertheless, the therapy proved effective, and the illness was eradicated.

Conclusion

The results of the follow-up research surprised the experts. The patient reported less low back pain during the fourth acupuncture treatment. A prolapsed lumbar intervertebral disc may be treated well with acupuncture (PLID)

References

1. Airaksinen O, Hildebrandt J, Mannion A, *et al.* European guidelines for the management of chronic nonspecific low back pain (Amended version June 14th 2005), 2004. http://www.backpaineuropa.org/web/files/WG2_Guidelines.pdf (accessed 5 Apr 2015).
2. Machado GC, Maher CG, Ferreira PH, *et al.* Efficacy and safety of paracetamol for spinal pain and osteoarthritis: systematic review and meta-analysis of randomised placebo controlled trials. *BMJ.* 2015;359:h1225.
3. Deyo RA, Von Korff M, Duhrkoop D. Opioids for low back pain. *BMJ* 2015;350: g6380. 4 van Middelkoop M, Rubinstein SM, Kuijpers T, *et al.* A systematic review on the effectiveness of physical and rehabilitation interventions for chronic non-specific low back pain. *Eur Spine J.* 2011;20:19-39.
4. Mixter WJ, Barr JS. Rupture of the intervertebral disc with involvement of the spinal canal. *N Engl J Med.* 1934;211:210.
5. Frymoyer WJ, Hailey EN, Howe J. A comparison of radiographic finding in fusion and nonfusion patients ten or more years following lumbar disc surgery. *Spine.* 1934;5:435.
6. Tang S, Qian X, Zhang Y, Liu Y. Treating low back pain resulted from lumbar degenerative instability using Chinese Tuina combined with core stability exercises: A randomized controlled trial. *Complementary Therapies in Medicine.* 2016;25:45-50.
7. Apley G, Solomon L. The back. In: Apley G, Solomon L (eds). *Apley's system of orthopaedics & fracture.* 7th edn. Oxford: Butterworth Heineman Ltd., 1993, 348-382.
8. Spangfort EV. The lumbar disc herniation: a computer aided analysis of 2504 operation. *Acta Orthop.*

- 1972;142(Suppl 2):1.
9. Su G, Zhou Z, Luo J. The clinical observation of treating lumbar disc herniation resulted from stagnancy of both blood and qi using acupuncture. *CJTTCM*. 2011;23:320-2.
 10. Kim KH, Kim YR, Baik SK, Noh SH, Kim DH, Lee SW. Acupuncture for patients with lumbar spinal stenosis: a randomised pilot trial. *Acupuncture in Medicine: Journal of the British Medical Acupuncture Society*. 2016;34(4):267-274. <https://doi.org/10.1136/acupmed-2015-010962>
 11. Qi Z, Xiao-gang Y. Clinical observations on the treatment of lumbar intervertebral disc protrusion by acupuncture and Tuina. *Journal of Acupuncture and Tuina Science*. 2005;3(6):39-41. <https://doi.org/10.1007/bf02851668>
 12. Zhang C. Protrusion of lumbar intervertebral disc treated by ultra-short wave and the point injection in 40 cases. *Chung iTsaChih Ying Wen Pan. Journal of Traditional Chinese Medicine*. 2003;23(1):43-44. <https://pubmed.ncbi.nlm.nih.gov/12747198/>
 13. Al DZP. Clinical observation on 32 cases of lumber intervertebral disc herniation treated by electro-acupuncture on Huatuo Jiaji points. *Journal of Traditional Chinese Medicine*, 2009. https://en.cnki.com.cn/Article_en/CJFDTotal-ZZYZ200907016.htm.